

Morphological Characteristics of Neonatal Adipose Tissue

Pepa ATANASSOVA, Gorana RANCIC, and Elenka GEORGIEVA

Accepted October 5, 2011

ATANASSOVA P., RANCIC G., GEORGIEVA E. 2012. Morphological characteristics of neonatal adipose tissue. *Folia biologica* (Kraków) **60**: 41-43.

The aim of the present work was to study the morphological characteristics of neonatal adipose tissue using rats as an animal model. The results revealed that the subcutaneous adipose tissue of newborns consists of packets of unilocular adipose cells (one large lipid drop occupying the whole cell and pushing the cytoplasm and the nucleus to the cell periphery) and some multilocular fat cells (several lipid droplets of different size and an almost centrally located nucleus). All the adipocytes demonstrated positive immunohistochemical expression for leptin, whereas the multilocular adipose cells were positive for cyclin D1. These findings suggest that the multilocular adipose cells are preadipocytes that have not yet finished proliferation and differentiation and could under some external and/or internal stimuli conclude their development and become mature unilocular adipocytes, thus increasing fat mass.

Key words: Preadipocytes, neonatal adipose tissue, leptin, cyclin D1.

Pepa Atanasova, Department of Anatomy, Histology and Embryology, Medical University of Plovdiv, 15a Vasil Aprilov Street, 4000 Plovdiv, Bulgaria.

E-mail: dr_pepa_atanasova@yahoo.com

Gorana Rancic, Institute of Histology and Embryology, Medical faculty of Nis, University of Nis, Boulevard of Zoran Djindjic 81, 18000 Nis, Serbia.

E-mail: goranaranc@medfak.ni.ac.rs

Elenka Georgieva, University of Plovdiv "P. Hilendarski", Faculty of Biology, Department of Developmental Biology, Section of Histology and Embryology 24 Tzar Assen Street, 4000 Plovdiv, Bulgaria.

E-mail: e_tomova@abv.bg

There are two different types of adipose tissue in adult mammals: white adipose tissue (WAT) and brown adipose tissue (BAT) that differ in their anatomical localization, histological appearance and functions (CINTI 2000; CINTI 2005; MAJKA *et al.* 2011). In adult rodents brown adipocytes are multilocular and express UCP as a marker protein (CINTI 2011; CINTI & MORRONI 1995), white adipocytes are unilocular and express leptin as a marker protein (CINTI *et al.* 1997; MASUZAKI *et al.* 1995). Sometimes it is difficult to differentiate between these two forms of adipose tissue as some authors, having in mind rats, report the occurrence of brown adipocytes in white adipose tissue (COUSIN *et al.* 1992). Due to the coexistence of WAT and BAT, the hypothesis of reversible physiological transdifferentiation has been developed, i.e. both tissues co-occur because they are able to convert one into the other (CINTI 2009; BARBATELLI *et al.* 2010). Information in the literature about neonatal adipose tissue is insufficient and concerns calves, cats and mice (ALEXANDER *et al.* 1975; LONCAR & AFZELIUS 1989; LONCAR 1991)

in which WAT is composed mainly of fully differentiated unilocular adipose cells, some fat cells with multilocular configuration and UCP mitochondria "typical" for brown adipocytes. Thus, adipose tissue at birth has the characteristics of both WAT and BAT. With increasing age, adipose tissue is converted into WAT for the rest of life (LONCAR & AFZELIUS 1989). Although poorly studied, the morphology of neonatal adipose tissue is of great importance because it may elucidate the detailed mechanisms of one of the clinical problems of modern civilization – obesity. The aim of the present work was to study the morphological characteristics of white subcutaneous adipose tissue of newborns, using rats as an animal model.

Material and Methods

The experiment was performed on 10 newborn rats, in line with protocols approved by the Institutional Animal Ethical Committee of Medical University-Plovdiv. Fragments of subcutaneous tissue

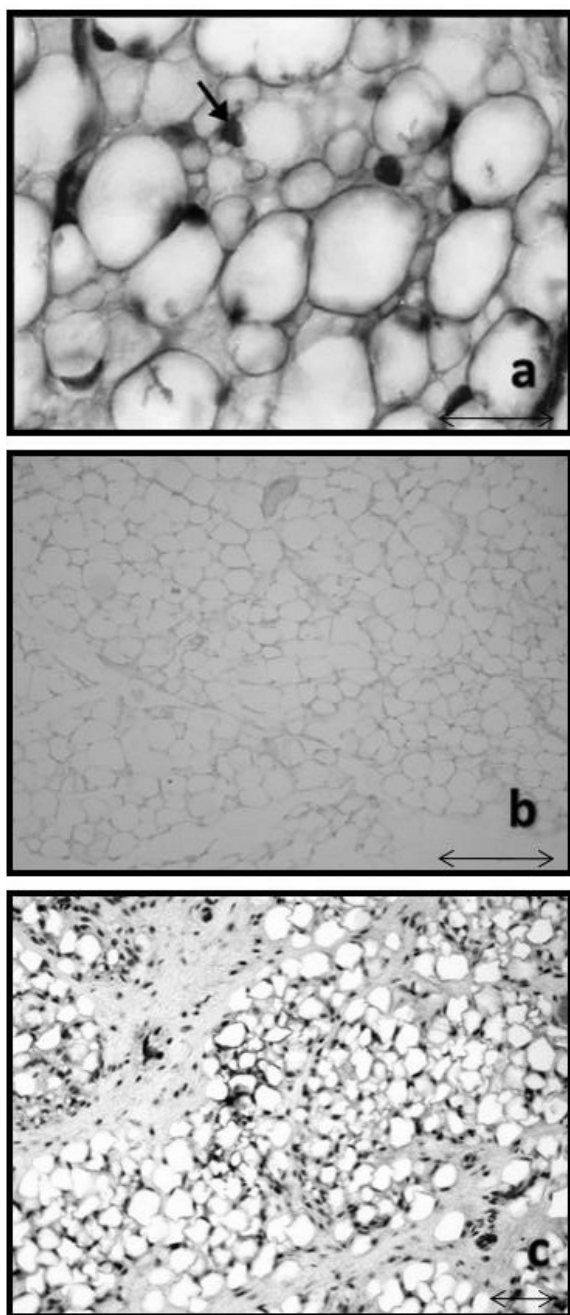


Fig. 1. a – Rat neonatal adipose tissue. (arrow multilocular adipose cells) H-E staining, x400; b – Leptin immunohistochemical expression in rat neonatal adipose tissue, x400; c – Cyclin D1 immunohistochemical expression in rat neonatal adipose tissue, x200.

from the gluteal region (sites of white adipose tissue formation) were prepared for histological investigation. Consecutive paraffin sections ($5\ \mu\text{m}$ thick) were prepared for hematoxylin-eosin staining, immunohistochemical demonstration of: (1) leptin by the avidin-biotin peroxidase (ABC) method using polyclonal rabbit anti-mouse leptin antibody (ALPHA Diagnostics, San Antonio, TX,

USA), diluted 1:5000 in PBS as primary antibody, according to a previously published protocol (ATANASSOVA & POPOVA 2000) cyclin D1 by the avidin-biotin peroxidase (ABC) method using polyclonal rabbit anti-mouse cyclin D1 antibody (Santa Cruz Biotechnology, Inc., USA) in dilution 1:200. The specificity of the immune reactions was confirmed by omission of the primary antibody.

Results

Light microscopy (hematoxylin-eosin) showed that the subcutaneous adipose tissue of the newborn rats consisted of already formed fat lobules. The lipid packets consisted mainly of unilocular adipocytes (roundish in shape, with one big lipid drop occupying almost the whole cell and a flattened nucleus situated in the cell periphery). Among these were cells with a multilocular configuration (smaller in size, round or irregular shape, with several lipid droplets and a nucleus in the centre or slightly pushed towards the periphery of the cell) (Fig. 1a). The immunohistochemical results revealed that all cells of the neonatal adipose tissue were positive for leptin (Fig. 1b). At the same time the multilocular adipose cells showed immunoreactivity for cyclin D (Fig. 1c).

Discussion

The results show that white adipose tissue at birth is formed predominantly by mature-like unilocular adipocytes and a small number of multilocular adipocytes. The configuration of the latter resembled that of brown adipocytes (COUSIN *et al.* 1992) but demonstrated positive immunohistochemical reaction for leptin. Keeping in mind that leptin is a marker for white adipocytes as this protein is produced and expressed exclusively by the white adipose tissue cells (MASUZAKI *et al.* 1995), we presume that the multilocular adipose cells in the gluteal region cannot be brown adipocytes present in the white adipose tissue of the newborns as it is in some animals (COUSIN *et al.* 1992). Because the gluteal region is a site of white adipose tissue formation and leptin is an immunohistochemical marker for adipocyte differentiation (ATANASSOVA & POPOVA 2000), we suggest that the multilocular cells are preadipocytes. Moreover, they show immunoreactivity for cyclin D1 which means that they are preadipose cells that have not yet finished their differentiation and maturation. Recently, expression of cyclin D1 was shown to occur in preadipocytes during early adipogenesis (FOX *et al.* 2008). We presume that there are two possibilities for the future of the mul-

tilocular preadipose cells: (1) the small lipid droplets fuse together into one big lipid drop – a transition from multilocular to unilocular adipocytes; (2) their preservation after birth. These preserved after birth resting cells under some internal or external stimulation could begin differentiating and turn into mature unilocular white adipocytes, thus increasing fat mass and explaining the mechanisms of obesity.

References

- ALEXANDER G., BENNETT J. W., GEMMELL R. T. 1975. Brown adipose tissue in the new-born calf (*Bos taurus*). *J. Physiol. Jan.* **244**: 223-234.
- ATANASSOVA P., POPOVA L. 2000. Leptin expression during the differentiation of subcutaneous adipose cells of human embryos *in situ*. *Cells Tissues Organs.* **166**: 15-19.
- BARBATELLI G., MURANO I., MADSEN L., HAO Q., JIMENEZ M., KRISTIANSEN K., GIACOBINO J. P., DE MATTEIS R., CINTI S. 2010 The emergence of cold-induced brown adipocytes in mouse white fat depots is determined predominantly by white to brown adipocyte transdifferentiation. *Am J. Physiol. Endocrinol. Metab.* **298**: E1244-53.
- CINTI S. 2000. Anatomy of the adipose organ. *Eat Weight Disord.* **5**: 132-142.
- CINTI S. 2005. The adipose organ. *Prostaglandins Leukot Essent Fatty Acids* **73**: 9-15.
- CINTI S. 2009. Reversible physiological transdifferentiation in the adipose organ. *Proc. Nutr. Soc.* **68**: 340-349.
- CINTI S. 2011. Between brown and white: Novel aspects of adipocyte differentiation. *Ann. Med.* **43**: 104-15.
- CINTI S., FREDERICH R. C., ZINGARETTI M. C., DE MATTEIS R., FLIER J. S., LOWELL B. B. 1997. Immunohistochemical localization of leptin and uncoupling protein in white and brown adipose tissue. *Endocrinology* **138**: 797-804.
- CINTI S., MORRONI M. 1995. Brown adipocyte precursor cells: a morphological study. *Ital. J. Anat. Embryol.* **100 Suppl.** **1**: 75-81.
- COUSIN B., CINTI S., MORRONI M., RAIMBAULT S., RICQUIER D., PÉNICAUD L., CASTEILLA L. 1992. Occurrence of brown adipocytes in rat white adipose tissue: molecular and morphological characterization. *J. Cell Sci.* **103**: 931-942.
- FOX K. E., COLTON L. A., ERIKSON P. F., FRIEDMAN J. E., CHA H. C., KELLER P., MACDOUGALD O. M., KLEMM D. J. 2008. Regulation of Cyclin D1 and Wnt10b gene expression by cAMP-responsive element-binding protein during early adipogenesis involves differential promoter methylation. *J. Biol. Chem.* **283**: 35096-35105.
- LONCAR D. 1991. Convertible adipose tissue in mice. *Cell Tissue Res.* **266**: 149-161.
- LONCAR D., AFZELIUS B. A. 1989. Ontogenetical changes in adipose tissue of the cat: convertible adipose tissue. *J. Ultrastruct. Mol. Struct. Res.* **102**: 9-23.
- MAJKA S. M., BARAK Y., KLEMM D. J. 2011. Concise review: adipocyte origins: weighing the possibilities. *Stem. Cells* **29**: 1034-40.
- MASUZAKI H., OGAWA Y., ISSE N., SATOH N., OKAZAKI T., SHIGEMOTO M., MORI K., TAMURA N., HOSODA K., YOSHIMASA Y., JINDAMI H., KAWADA T., NAKAO K. 1995. Human obese gene expression. Adipocyte-specific expression and regional differences in the adipose tissue. *Diabetes* **44**: 855-858.